

Received: 2019.02.14

Accepted: 2019.04.01

Published: 2019.09.13

Ankle Joint Position and the Reliability of Ultrasound Tissue Characterization of the Achilles Tendon: A Pilot Study

Authors' Contribution:
Study Design A
Data Collection B
Statistical Analysis C
Data Interpretation D
Manuscript Preparation E
Literature Search F
Funds Collection G

ABCDEF 1 Arturo Lawson
BE 1 Marika Noorkoiv
BDE 2 Lorenzo Masci
E 1 Amir A. Mohagheghi

1 Centre for Human Performance, Exercise and Rehabilitation, Brunel University, London, U.K.
2 Pure Sports Medicine, London, U.K.

Corresponding Author: Arturo Lawson, e-mail: arturo.lawson@brunel.ac.uk
Source of support: Departmental sources

Background: Imaging of the Achilles tendon using ultrasound tissue characterization (UTC) involves taking up the slack of the tendon by including dorsiflexion of the ankle. This pilot study aimed to determine whether different longitudinal tension applied to the Achilles tendon during imaging affected the reliability of UTC.





Material/Methods: Nine asymptomatic active volunteers, aged between 23–49 years underwent imaging of 17 Achilles tendons. Three positions of tension included plantar grade, 50%, and 100% of maximal dorsiflexion, with a range of 18–32°. Ranges were established and standardized using an isokinetic dynamometer. A test and re-test process was conducted at each position to determine the intraclass correlation coefficients (ICCs) and minimum detectable change (MDC) per echotype. Images were analyzed using UTC software.

Results: Plantar grade positioning images could not be obtained. ICCs for each echotype I–IV between test 1 and test 2 were 0.965, 0.962, 0.858, 0.739 at 100% dorsiflexion (95% CI, 0.86–0.99, 0.84–0.99, 0.51–0.97, and 0.2–0.94), and 0.771, 0.551, 0.569, 0.429 at 50% dorsiflexion (95% CI, 0.29–0.94, –0.09–0.88, –0.01–0.88, and –0.15–0.82). The MDC per echotype I–IV ranged between 4.1–1.0% of echotype data at 100% dorsiflexion, and 17.2–6.3% at 50% dorsiflexion.

Conclusions: Testing at maximum dorsiflexion provided improved reliability when using UTC in healthy individuals. The ICC at 100% dorsiflexion was increased, and the MDC was reduced for all echotypes. Therefore, standardizing test positions when using UTC is advisable for reliable comparison of results between studies.

MeSH Keywords: **Achilles Tendon • Reproducibility of Results • Tendinopathy • Ultrasonography**

Full-text PDF: <https://www.medscimonit.com/abstract/index/idArt/915685>

 5193  4  2  48



Background

The Achilles tendon (AT) is the strongest tendon in the body, being able to withstand large forces before failure occurs [1]. However, as a result of the large loads placed upon it, it can develop pathological changes in its structure, leading to pain and dysfunction in a variety of population groups [2]. The changes commonly seen in tendon pathology include cellular over-activity and proteoglycan over-expression that results in disruption of collagen fascicular organization leading to the breakdown of the extracellular matrix [3]. Tendon pain is often gradual in onset and may present as minor repetitive episodes of discomfort following activity that may ultimately develop into the clinical features of persistent pain, focal or widespread swelling, reduced range of motion at the ankle, and pain on palpation. Deficits in strength in the triceps surae muscle group are also common [4]. This collective presentation of features and loss of function is classed as Achilles tendinopathy [5].

Initial diagnosis of Achilles Tendinopathy can be made in the clinical setting following history taking, thorough testing, and the evaluation of painful responses to activities such as hopping, jumping, and heel raises. Assessment of the structure of the Achilles tendon in health and disease is possible with imaging techniques [6]. Magnetic resonance imaging (MRI) and B-mode ultrasonography are commonly used to view changes associated with Achilles tendinopathy. While MRI may show an increase in tendon size due to increase fluid uptake in the tendon, ultrasonography is more economical to use. In addition to evaluating tendon shape and size, it also shows matrix integrity due to the acoustic response of the ultrasound beam and its interaction with collagen fiber arrangement [7]. Ultrasound is used in the assessment of tendon health based on acoustic impedance and quantification of echogenicity. Healthy tendon contains densely packed collagen structures that align parallel to the tendon axis, and this is represented by hyperechoic images or brightness in the tissue [7]. Conversely, the damaged matrix has reduced collagen density, and this is reflected by darker areas of hypoechoic tissue [8–10]. One limitation of ultrasound is its subjectivity in interpretation by the user [10].

A novel and increasingly popular method of tendon assessment with imaging is ultrasound tissue characterization (UTC), which uses B-mode ultrasound and specific algorithms within the device software (UTC 2010, UTC Imaging) to create a 3D image of the tendon by capturing contiguous frames at intervals of 0.2 mm over 12 cm of tendon (600 images) [11]. The device can differentiate fiber size by assessing relative grey images and reflections. Once contouring of the tendon has been completed, images are represented visually on screen in different colors for analysis to indicate different tendon fascicle size, organizational quality, and relative stability, which allows

semi-quantification of tendon structure [11]. Echotype I represents maximum stability with intact and aligned fiber bundles, echotype II represents medium stability with discontinuous wavy bundles, echotype III represents a highly variable matrix with smaller fibrillar material, and echotype IV shows mostly amorphous tissue with constant low intensity and a variable distribution [11]. Healthy tendons are expected to have a higher content of echotype I and II, and more echotype III and IV when diseased.

Correlation between levels of tissue damage and repair with these echotypes have been demonstrated in an equine model [12–18]. It follows that representation of altered matrix integrity is based on correlations with varying acoustic changes within the tendon.

UTC has been used to observe short-term changes in tendon structure over days [19,20], mid-term changes over weeks and months [21] and to evaluate the structural effects of a variety of treatments on the Achilles tendon and the patella tendon in humans [22–25].

To obtain an image that can be analyzed for tissue integrity, the slack of the Achilles tendon is usually taken up in testing protocols by adding dorsiflexion to the ankle, therefore, eliminating the natural sag of the tendon. Without removing the natural sinking of the Achilles tendon, a straight contour for the positioning of the UTC tracker is not possible. The resultant effect is that ultrasound waves from the probe cannot penetrate the tissues at a perpendicular angle to the skin which creates an anisotropic event, which is detrimental for precise image collection and viewing [11]. Furthermore, the tendon has fibrillar components arising from the medial and lateral gastrocnemius and soleus muscle, and slack in these muscles is taken up at different ankle positions [26]. It would follow that the Achilles tendon may also be influenced by such an increase in passive elastic force when dorsiflexion is increased. When the tendon and gastrocnemius are observed for the onset of slack with shear wave elastography, the passive tendon force begins in more plantar flexion than in the muscle, as demonstrated by an earlier increase in the shear wave velocity [27]. This finding is not entirely surprising given that the tendon is stiffer than the muscle and would expectedly reach the end of its slack position in the movement towards dorsiflexion. Importantly, it is difficult to establish the point where maximum passive force is achieved in the tendon using elastography, as due to equipment limitations, saturation occurs before reaching the maximum position of stretch.

Optimizing homogeneity in structural alignment can, therefore, improve image quality, which is of relevance in the assessment of tendon health and monitoring progression of tendon health through a treatment cycle. Despite the need for

Table 1. Demographic information of the study participants who underwent imaging of the Achilles tendon using ultrasound tissue characterization (UTC).

n=9	Weight kgs	Height m	Age	BMI kg/m ²	VISA-A
Mean	68.9	1.7	34.6	24.6	96
SD	13.2	0.1	10.0	3.6	5
Median	66.4	1.7	31.0	23.5	99

such homogeneity, methods reported in studies using UTC have reported a variety of approaches to standardizing ankle dorsiflexion positions, with positions in prone ranging from full dorsiflexion [11] to 5–10 degrees of dorsiflexion [23]. Other methods have included prone positions and positions with the ankle pushed into a dorsiflexion stretch [28], standing [20,21], or the use of a frame for maintaining a fixed position [25,29]. Inter-observer reliability is reported high in previous studies [11,29], but there is no clear guidance on how much dorsiflexion is optimal for the assessment of the tendon, whether the echotype percentages alter beyond a minimum value that achieves removal of the sag of the tendon, or if any of the above-described positions are superior to any other.

This variability in methods presents a challenge to interpreting and comparing results between studies using UTC, as different amounts of passive force, altered fascicle orientation, and any induced tonic stretch reflex due to the imposed stretch could create variations in echotype representation and error of measurement. Standardizing test procedure in the clinical setting is also essential for the evaluation of the progression of structural integrity over time. To the best of our knowledge, no study has shown the optimal ankle angle for reliable measurement using UTC.

The primary aim of the study was to quantify the most conservative margin of measurement error in determining tendon organizational integrity by comparing the test-retest reliability of measures for all echotypes obtained using UTC in non-symptomatic Achilles tendons. Three different positions at the ankle were used to determine the most optimal position for testing. Therefore, the intraclass correlation coefficients (ICCs) for each echotype were calculated after repeating measurements at each position. The minimum detectable change (MDC) was calculated to determine which position showed the most conservative margin of measurement error. A secondary aim of this pilot study was to identify the best testing position when using UTC. To this end, we observed whether echotype values differed above the MDC in each test condition. It was hypothesized that maximizing stretch in the muscle-tendon unit or increasing the dorsiflexion angle, would increase the reliability of the measurements by optimizing structural organization in the tendon.

Material and Methods

Participants

Nine asymptomatic participants (M=4; F=5) from staff and students of Brunel University London were invited to participate in this pilot study, following approval from the College of Health and Life Sciences Research Ethics Committee (dated 22 Sept 2016). Written consent was obtained from each participant. Inclusion criteria were no prior Achilles tendon problems and active participation in sport at least three times per week. Candidates were excluded if they had previously undergone any injection therapies or rupture of the Achilles tendon, or had a prior ankle injury that limited range of motion (ROM). Both Achilles tendons were included for testing in each participant. Age and activity levels were noted by the research team to ensure reaching the threshold.

The Victorian Institute Sport Assessment-Achilles (VISA-A) is a valid and widely used questionnaire that determines functional ability and clinical severity in Achilles tendinopathy [30]. Scores were collected for each participant to confirm the absence of current and restrictive problems in the Achilles tendon (Table 1).

Positioning

Ankle range of motion (ROI) can vary according to gender, age, and individual variation in flexibility. To establish a reliable method to determine ankle dorsiflexion and allow normalization between participants, an isokinetic dynamometer (Biodex Med Systems Inc., New York, NY, USA) was used to establish an angle for maximum dorsiflexion (100%) which ranged between 18–32° between participants, taken from the 0° position, where the foot was neither plantar flexed nor dorsiflexed (plantar grade). End range dorsiflexion was established by moving the ankle by hand until no further comfortable movement was possible. To avoid any unwanted reflex muscle activity due to pain, the final position held was just before the threshold of discomfort. The dynamometer footplate was then fixed at that point. Once maximum dorsiflexion was noted and data collected, a mid-way point was established for the second measure at 50% dorsiflexion and the footplate fixed, as before. Finally, the position of the plantar grade was the third

point of measure, which was established by placing the dynamometer footplate at zero degrees. Ultrasound images were collected at 100% dorsiflexion and 50% dorsiflexion and the plantar grade position. No torque data was collected as only passive stretch positioning was deemed relevant in this study, as it is the more common clinically applicable method.

Ultrasound tissue characterization (UTC) data collection

An ultrasound tissue characterization (UTC) device (UTC Imaging, Stein, the Netherlands) was used to visualize the Achilles tendon. A 7–12 MHz linear ultrasound probe (Teratech, Rutherford Appleton Laboratory, Harwell, Oxfordshire, UK) was mounted on a tracker designed to fit around the contour of the lower leg to maintain a steady position for the probe for image collection. The ultrasound probe was placed parallel to the Achilles tendon in a longitudinal position, with the edge of the tracker at the most proximal point of the calcaneus. Ultrasound gel was placed between the tracker and the skin and the ultrasound probe, as previously described [11].

Data collection was over a 12 cm length of the tendon, as this was an established protocol dictated by the relationship between the tracker and the probe [11]. Images were captured from distal to proximal. The first sequence of image collection was carried out on the participants' left leg, in full dorsiflexion position, then after repositioning to 50% dorsiflexion, the second set of images were collected for the left leg, and finally, the ankle was repositioned to plantar-grade for the third set of images. Image collection in this position was discontinued early in the process due to persistently poor image quality. The process was repeated on the right leg, to compare echotype values between test positions and therefore both full sets of images for right and left leg ($n=17$) were used in the analysis for observation in differences in echotype values between both dorsiflexion positions of testing. Following image collection for each leg in both positions, reliability testing involved a repeat of this imaging process for the left leg once again ($n=9$) using the same order detailed above, therefore allowing a time lag of approximately 20 minutes between collection of the first set to the second set of images for the left leg. Together with ICC for reliability, looking at the minimum detectable change (MDC) for clinical investigations is an important calculation to determine whether changes are due to testing error or a real difference in condition.

The chosen ROI for each scan was from the superior calcaneal border, at the point that the shelf of the calcaneus dips anteriorly, to the point of appearance of the distal fibers of the soleus, to only gather data from the Achilles tendon. This distal point was chosen as it was desirable to exclude the insertional area of the Achilles tendon, as this has been shown to have relatively higher levels of echotype II than the mid-portion [30] and our interest was only on the more proximal section of the tendon.

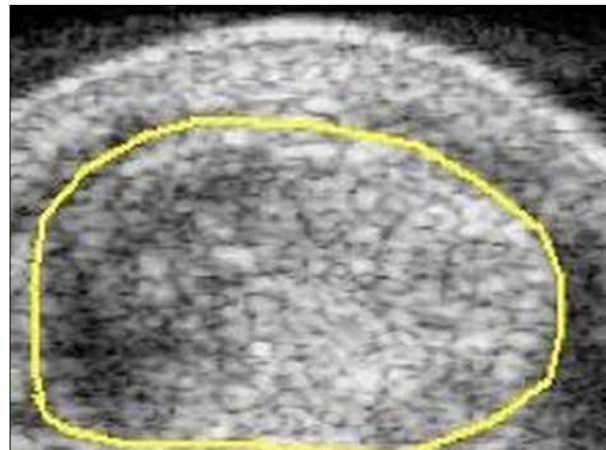


Figure 1. Greyscale transverse image of the Achilles tendon with the margins contoured.

For analysis, the tendon was contoured from the most distal point of the region of interest (ROI), as described above, in a transverse view in greyscale, using the UTC device software version 1.0.6 (Figure 1). Contouring was performed at 0.5 cm intervals along the free tendon for interpolation to create a three-dimensional block that would then be analyzed for echotype composition. Collected data were analyzed in order of collection in each position for each participant, which allowed considerable time lapse between analysis of echotypes for any given participant in each position and minimized recall of values to eliminate bias (Figure 1).

Data analysis

Collected UTC images were analyzed using the UTC setting at window 9, which gathered contiguous images at intervals of 1.8 mm, giving it the highest possible resolution using UTC. Statistical analysis of each of the echotype values, including Wilks–Shapiro test for normality, was performed using IBM SPSS Statistics version 20.0 for Windows. Data were reported as the absolute percentage values of each echotype present in the ROI. The ICC was equated for each test position. A distribution-based model of MDC was reported for each test position as the standard error of measurement (SEM) by the formula:

$$SD \times (\sqrt{1 - ICC})$$

The MDC was calculated using the formula:

$$1.96 \times SEM \times \sqrt{2}$$

Results

Characteristics of the study participants

The age of the study participants ranged from between 22–49 years. The Victorian Institute Sport Assessment-Achilles (VISA-A)

Table 2. Intraclass correlation coefficient (ICC) and 95% confidence interval (CI) for each echotype under each test condition used in imaging of the Achilles tendon using ultrasound tissue characterization (UTC).

	Echotype			
	I	II	III	IV
100% DF				
ICC	0.97	0.96	0.86	0.74
95% CI	0.86–0.99	0.84–0.99	0.51–0.97	0.2–0.94
50%DF				
ICC	0.77	0.55	0.57	0.43
95% CI	0.29–0.94	–0.09–0.88	–0.01–0.88	–0.15–0.82

Table 3. Intraclass correlation coefficient (ICC) and minimum detectable change (MDC) for each echotype under each test condition used in imaging of the left Achilles tendon using ultrasound tissue characterization (UTC).

n=9	100% dorsi-flexion				50% dorsi-flexion			
	I	II	III	IV	I	II	III	IV
MEAN	57.08	37.44	4.17	1.31	51.40	36.04	9.26	3.30
SD	8.0	5.0	2.0	1.0	13.0	4.0	10.0	3.0
ICC	0.965	0.962	0.858	0.739	0.771	0.551	0.569	0.429
MDC	4.1%	2.7%	2.0%	1.0%	17.2%	7.4%	18.2%	6.3%

questionnaire scores ranged from between 87–100 (see Table 1). All participants took part in exercise activity for a minimum of 30 minutes at least three times per week (Table 1).

The ankle positions were plantar grade, 50% dorsiflexion, and 100% dorsiflexion. Range of maximum dorsiflexion was between 18–32° from the neutral position, with a mean of 27° and a median of 28° and standard deviation (SD) of 4°.

Seventeen tendons were imaged and analyzed. The image for one tendon at 50% dorsiflexion was poor, and so it was not included for analysis. The attempt to collect data at plantar grade ankle position was discontinued almost immediately as the images gathered were repeatedly of poor quality, defined by variable anisotropy and lacking continuous and clearly defined tendon borders, thus leaving two positions for testing. The data were normally distributed for echotypes I and II, but not for echotypes III and IV, which could have been due to the relatively small values in echotypes III and IV in non-symptomatic tendons and the small dataset of participants.

Reliability of position analysis

The intraclass correlation coefficient (ICC) was calculated using a two-way mixed analysis for absolute agreement to measure the reliability between test and re-test for each condition to determine whether either condition gave more reliable

measures for repeatability. The ICC for each echotype and in each test condition can be found in Table 2. Most significant values for ICC were found for the position of 100% dorsiflexion in all echotypes ranging from 0.97 for echotype I to 0.74 for echotype IV. However, the highest ICC in the 50% dorsiflexion position only reached 0.77 in echotype I and lowest in echotype IV at 0.43 (Table 2).

The values for MDC in the 50% dorsiflexion test condition showed much higher error values for all echotypes (Table 3). Echotype I had an MDC of 4.1% for 100% dorsiflexion compared with 17.2% in 50% dorsiflexion. Echotypes II, III, and IV also had lower MDC values in 100% dorsiflexion, all were <3% compared with the position of 50% dorsiflexion, which ranged above 6–18% (Table 3).

Between-condition analysis

Table 4 shows the means and SD for each echotype under each test condition of 100% dorsiflexion and 50% dorsiflexion. Figure 2 shows individual echotype I values and how they were lower in 12 tendons in 50% dorsiflexion, and were virtually the same in two tendons when compared with the 100% dorsiflexion position. Only in two tendons were echotype I values expressed marginally higher. Echotype II was very similar in both positions and echotype III+IV, as reciprocal measures of echotypes I and II, were predictably higher in 50% dorsiflexion.

Table 4. The mean and standard deviation (SD) between different test positions used in imaging of the Achilles tendon using ultrasound tissue characterization (UTC).

n=17 tendons	100% DF	I	II	III	IV	50% DF	I	II	III	IV
% echotype	Mean	56.2	38.7	3.9	1.2	Mean	50.9	38.7	7.9	2.6
	SD	7.2	5.2	2.3	0.9	SD	11.7	6.2	8.2	2.7

One participant's Achilles tendon imaging at 50% dorsiflexion was of poor quality and was excluded from analysis.

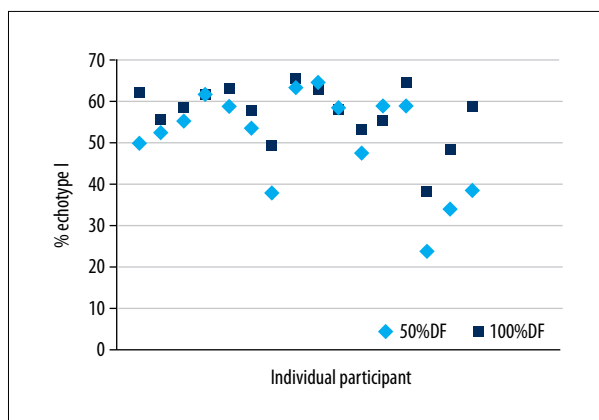


Figure 2. Individual echotype I absolute values in each of the test positions of the Achilles tendon.

Although the main objective of the study was not aimed at actual echotype measure in each tendon, it was relevant to observe if differences in values existed between each test position that was larger than the MDC. This finding supported the need to consider the position when testing for tendon structural (Table 4, Figure 2).

The difference between values in echotype I in each test position for most tendons, while modest at about 10%, exceeded the MDC calculated for the 100% dorsiflexion position, therefore highlighting a difference between positions that were higher than acceptable values due to a testing artifact, and should be considered as relevant.

Discussion

The main aim of this study was to measure the most conservative margin of measurement error in determining tendon organizational integrity. We determined the reliability of imaging of the Achilles tendon using ultrasound tissue characterization (UTC) when tested in two different positions of ankle dorsiflexion. The findings showed that imposing maximum passive stretch on the muscle-tendon unit when positioning the ankle at the maximum dorsiflexion angle increased the reliability of the measurements, as shown by a higher intraclass correlation coefficient (ICC) and a lower minimum detectable change (MDC) per echotype. The MDC values using maximum

dorsiflexion gave us a comparable threshold of error of measurement that has also been shown in previously published studies. [20,21,31,32]. Testing the tendon at 100% dorsiflexion at the ankle provides a smaller variation in the measurements, and provides a more reliable measure of acoustic impedance and, by association, structural integrity.

Previous studies [7,33] have shown that variation in echogenicity is reduced with increasing passive stretch of the triceps surae muscle muscle-tendon unit, and this reduction is particularly noticeable with higher ranges of dorsiflexion. Given that UTC semi-quantification of tendon structure relates to echogenicity of the tissues creating a given echotype, creating reliable images is critical for reassessment during treatment. Research using UTC is becoming more extensive, but different methods of tensioning the Achilles tendon have been used. Therefore, to make comparisons between studies, consistency in techniques of testing should be advocated.

Consideration must be given to the different stiffness of the Achilles tendon compared with muscle (tendon is stiffer) during the passive stretch, emphasizing the need for the maximum stretch on the muscle-tendon unit if the tendon is to be assessed. The lower magnitude of the imposed strain on the muscle-tendon unit may be insufficient to optimize collagen orientation within the Achilles tendon, despite taking up slack earlier in the tendon when moving towards ankle dorsiflexion [27]. In contrast, although muscle activation also stretches the tendon, echogenicity does not appear to significantly change beyond 30% of maximal voluntary contraction (MVC) torque of plantar flexor contraction [7]. Collagen fibers do not alter in orientation beyond the toe region of strain during an active contraction. Comparisons of echotype profile between the actively and passively induced stretch of the tendon has not been investigated using UTC, but it possibly adds a further layer of unnecessary complexity when used clinically that may not add relevant information for patient management. However, it must be acknowledged that differences may exist in echotype values if the active and passive stretch of the Achilles tendon were to be compared.

Given that testing the tendon in its extreme position of stretch will eliminate crimp, it will, therefore, allow less variation in passive tension within the tendon fascicles. This factor is of

relevance for repeatability in clinical testing in that the extreme is easier to determine rather than any arbitrary position of dorsiflexion. Therefore, maximum passive tension in dorsiflexion makes it easier for the operator to standardize positioning. The test-retest analysis in this study demonstrated that full dorsiflexion positioning ensured the best ICC values and showed the best repeatability of the methods. There have been no previous studies that have investigated the reliability of measures in different test positions, despite intra-operator reproducibility having been described as high in previous studies [11,34].

When applying forces to the Achilles tendon and evaluating the structure, it is relevant to consider that strain throughout the tendon is not uniform. There is a greater displacement in the proximal compared with the distal Achilles tendon [35], and also more on the ventral side compared with the dorsal side [36,37], with compressive forces also being highest in the deeper parts of the tendon [38]. Inter-fascicular sliding is a feature of particular relevance in energy storing tendons such as the Achilles tendon, further contributing to heterogeneous longitudinal tendon loading [39]. Finally, there is also a transverse rotation of the free tendon under isometric tension, which is maximal at the mid-portion, consistent with the direction of the spiral of tendon fascicles [40]. This finding also creates a change in tendon cross-sectional area, which may also be relevant when comparing the results to the passive stretch conditions where the induced tension would be expected to be shared between muscle and Achilles tendon, rather than by the Achilles tendon alone. These features of heterogeneous tension development in the Achilles tendon under different conditions reinforces the need to find a position and testing condition that may minimize these variations.

A secondary aim in this study was to determine the best testing position when using UTC. We determined values for each echotype in each test position. The MDC gives a threshold where error due to test procedure may occur. Differences in echotype values between test conditions above the MDC can be considered as an actual effect and not due to test error. The tendon showed consistently higher individual values in echotypes I in full dorsiflexion. Echotypes II showed inconsistent values per participant. Echotypes III/IV consistently showed lower content when in full dorsiflexion, with means of 4% compared with 8% at the half dorsiflexion position. When the Achilles tendon is tense during imaging, there may be an overestimate of the echotypes associated with underlying pathology. If imaging positioning is variable between assessment sessions, changes in echotype may be inadequately represented. The echotypes III/IV are considered to represent small fibrillar or amorphous fluid dominated matrix and are a reciprocal value of types I and II echotypes, and so significant changes between positions of testing in this study would be unlikely given the

small amounts reported in healthy tendons. It would be expected that symptomatic tendons would have a higher component of III/IV echotypes and may, therefore, show more variation by a change in the test position.

It is important to explore each echotype result individually, as due to the heterogeneous nature of the tendon makeup, tension will be experienced differently throughout the tendon [41], and it is possible that the more robust fibril represented by echotype I may be more resistant to deformation than the smaller, less organized type III in a healthy tendon. Adding maximum dorsiflexion into the test position ensures all fibers are under tension, regardless of size and quality. Reliability of measurements using UTC could be influenced by activity before testing, which is particularly important if the progression of Achilles tendinopathy is under review. The effect of activity over 24 hours has been previously reported [20], but a recent report investigating the effect of running on immediate and short-term changes in echotypes showed no differences after 20 minutes of running [42]. This finding is not surprising, as changes that are likely to be due to fluid exchange in the tendon [43] may not affect healthy matrix composition to such a degree that it would change the structure as detected by UTC.

Change in tendon anteroposterior (AP) diameter has been suggestive of flux in fluid content within the tendon matrix, which has been shown to vary even following brief activity [44]. The change in AP diameter is reduced in tendinopathic tendons, possibly as a result of reduced fluid extrusion due to increased proteoglycan content (aggrecan and versican) in diseased tendons [44,45]. Such proteoglycan imbalance increases the water within the ground substance of the matrix contributing to the loss of fascicle organization and deterioration of the tendon structure. These features of possible disorganization or adaptations were also previously observed in a study investigating the effect of short-term loading in Australian football players [20]. An increase in echotype III and particularly IV will reflect these changes of disruption in the matrix with existing pathology due to increased proteoglycan content and subsequent binding of water.

This pilot study used a small study sample size of nine participants (17 tendons studied), with no current history of Achilles tendinopathy and no previous recent trauma. Given the differences in strain seen between healthy and pathological Achilles tendons [44], and the variation in fluid exchange that could affect matrix echogenicity, extrapolation of the data found in this study on positional reliability measures when investigating echotypes in unhealthy tendons, should be considered with some caution. The triceps surae, Achilles tendon, and the aponeurosis, exhibit variation in comparative stiffness properties, and when subjected to longitudinal stretch, are likely to have differential areas that are subject to more or less strain [32].

Also, shear occurs between the soleus and gastrocnemius on passive and active tasks [46,47]. These variations in strain properties could produce inconsistencies in assessment with imaging, possibly due to variations in acoustic properties. As UTC is a tool to clinically assess an individual from the first contact and during the course of treatment, these stiffness variations are of no consequence to the results of any given individual, as long as the most consistent and reliable test position is used each time the Achilles tendon is assessed.

Furthermore, the muscle-tendon unit is a viscoelastic tissue and will change its response to tension after successive repositioning. In this study, this potential confounder may have been minimized by the time delay between tests for each condition, and conditioning of the muscle or tendon may not have been a required prerequisite.

There are two operational considerations with testing reliability in UTC. The first one is operator reliability. A common undesirable feature with a sonographic investigation is image anisotropy due to poor contact when the probe is not set at optimal positioning to the tendon, either for longitudinal or transverse viewing [7]. This problem is minimized using UTC because the image taken is using a probe mounted on a tracker that maintains the probe parallel to the limb. The tracker is contoured to allow positioning according to the natural shape of the calf. Also, as the tracker moves at a steady rate to cover the tendon length, the required contiguous images required to construct a three-dimensional block of tendon for analysis are automatically taken. The only confounder will be an unsteady hand when applying the tracker device.

The second consideration for reliability is the analysis for quantification of echotypes, which requires the contouring of the tendon in a transverse view using greyscale images at chosen intervals so that the software can form the block or region of interest that will be analyzed for echotype content. The contouring requires careful delineation of the tendon margins and appreciation of the changing shape of the Achilles tendon from its distal crescent shape to its more proximal oval appearance [48]. Finally, accuracy in identifying the location of the proximal end of the free Achilles tendon at the point of origin of the soleus aponeurosis is needed, if the free tendon is chosen to be studied in isolation.

The strength of this preliminary study was the way that the position for testing was determined by the use of a dynamometer, which gave accurate and quantitative measures for establishing positions of dorsiflexion. The limitations of this study include the reliability considerations between intra-session and inter-session testing. Reliability between sessions is perhaps more relevant when UTC is used to monitor changes over time in the clinical setting, and further studies should consider

investigating this. Error due to repositioning in different tensions was minimized by the procedure of using a dynamometer to calculate exact angles of dorsiflexion. The small sample size used in this study also only allowed a descriptive investigation. Therefore, the information gained from this study should form the basis for larger studies that can further investigate the relevance of tension applied in testing. Another possible limitation of this study was that contouring was not repeated at a separate time point to evaluate the reliability of the investigator in performing the contouring. Also, the use of window 9 at a higher resolution for analysis may detect movement artifact during image acquisition, which could have affected the results. The other available options for window size are 17 and 25. Each window will sample several contiguous images every 0.2 mm, so that stability of the echo-pattern is assessed over a different proportion of the Achilles tendon. Therefore, window 9 will evaluate 0.2×9 images = 1.8 mm for assessment, window 17 will evaluate $0.2 \times 17 = 3.4$ mm, and window 25 will evaluate $0.2 \times 25 = 5$ mm. As with any focusing device, the level of detail obtained at high resolution could be mitigated by artifact error. It would be wise to compare analysis data using different window sizes to observe if any differences exist with positioning. Unpublished data in normal and pathological tendons have shown some difference in echotype distribution, with window 9 showing the least echotype I, but this finding was statistically insignificant when window size was compared.

Further studies should consider inter-session reliability measures, comparison of echotypes in different positions using different window sizes for analysis, and comparisons between passive stretch on the tendon and stretch during isometric contraction, with some consideration to tendon conditioning before testing. Finally, a comparison between reliability measures obtained in symptomatic and asymptomatic Achilles tendons is advised so that clinical testing recommendations can be made.

Conclusions

This pilot study aimed to determine whether different longitudinal tension applied to the Achilles tendon during imaging affected the reliability of ultrasound tissue characterization (UTC). The findings showed that testing at maximum dorsiflexion provided improved reliability when using UTC in healthy individuals. The intraclass correlation coefficient (ICC) at 100% dorsiflexion was increased, and the minimum detectable change (MDC) was reduced for all echotypes. Therefore, standardizing test positions when using UTC is advisable for reliable comparison of results between studies, as UTC is not only used to evaluate tendon structural integrity but also to reassess tendon health during and after treatments.

Acknowledgments

The authors thank Jarrod Antflick for permission, guidance, and use of the ultrasound tissue characterization (UTC) analyzer used in this study.

References:

- Arya S, Kulig K: Tendinopathy alters mechanical and material properties of the Achilles tendon. *J Appl Physiol*, 2010; 108: 670–75
- Abat F, Alfredson H, Cucchiari M et al: Current trends in tendinopathy: Consensus of the ESSKA basic science committee. Part I: Biology, biomechanics, anatomy and an exercise-based approach. *J Exp Orthop*, 2017; 4: 18
- Riley G: Tendinopathy – from basic science to treatment. *Nat Clin Pract Rheumatol*, 2008; 4(2): 82–89
- Jarvinen T, Kannus P, Maffulli N, Khan K: Achilles tendon disorders: Aetiology and epidemiology. *Foot Ankle Clin N Am*, 2005; 10: 255–66
- Cook J, Purdam C: Is tendon pathology a continuum? A pathology model to explain the clinical presentation of load-induced tendinopathy. *Br J Sports Med*, 2009; 43: 409–16
- Docking S, Ooi CC, Conell D: Tendinopathy: Is imaging telling us the entire story? *J Orthop Sports Phys Ther*, 2015; 45(11): 842–52
- Ishigaki T, Kouno M, Ikebukuro T, Kubo K: Quantification of collagen fiber orientation in human tendons with the coefficient of variation of echogenicity. *J Biomech*, 2016; 49(16): 3923–27
- Goss SA, Frizzell LA, Dunn F: Ultrasonic absorption and attenuation in mammalian tissues. *Ultrasound Med Biol*, 1979; 5: 181–86
- Nicoll RG, Wood AKW, Rothwell LTW: Ultrasonographical and pathological studies of equine superficial digital flexor tendons; Initial observations including tissue characterization by analysis of image grey scale, in a thoroughbred gelding. *Equine Vet J*, 1992; 24: 318–20
- Del Buono A, Chan O, Maffulli N: Achilles tendon: functional anatomy and novel emerging models of imaging classification. *Int Orthop*, 2013; 37(4): 715–21
- van Schie HTM, de Vos RJ, de Jonge S et al: Ultrasonographic tissue characterisation of human Achilles tendons: quantification of tendon structure through a novel non-invasive approach. *Br J Sports Med*, 2010; 44: 1153–59
- van Schie HTM, Bakker EM: Structure-related echoes in ultrasonographic images of equine superficial digital flexor tendons. *Am J Vet Res*, 2000; 61(2): 202–9
- van Schie HTM, Bakker EM, Cherdchutham W et al: Monitoring of the repair process of surgically created lesions in equine superficial digital flexor tendons by use of computerized ultrasonography. *Am J Vet Res*, 2009; 70(1): 37–48
- van Schie HTM, Bakker EM, Jonker AM, van Weeren PR: Ultrasonographic tissue characterization of equine superficial digital flexor tendons by means of grey level statistics. *Am J Vet Res*, 2000; 61(2): 210–19
- van Schie HTM, Bakker EM, Jonker AM, van Weeren PR: Efficacy of computerized discrimination between structure-related and non-structure-related echoes in ultrasonographic images for the quantitative evaluation of the structural integrity of superficial digital flexor tendons in horses. *Am J Vet Res*, 2001; 62(7): 1159–66
- van Schie HTM, Bakker EM, Jonker AM, van Weeren PR: Computerized ultrasonographic tissue characterization of equine superficial digital flexor tendons by means of stability quantification of echo patterns in contiguous transverse ultrasonographic images. *Am J Vet Res*, 2003; 64(3): 366–75
- Cadby JA, David F, van De Lest C et al: Further characterisation of an experimental model of tendinopathy in the horse. *Equine Vet J*, 2013; 45: 642–48
- Bosch G, van Weeren PR, Barneveld A, van Schie HTM: Computerised analysis of standardised ultrasonographic images to monitor the repair of surgically created core lesions in equine superficial digital flexor tendons following treatment with intratendinous platelet rich plasma or placebo. *Vet J*, 2011; 187: 92–98
- Waugh C, Alktebi T, de Sa A, Scott A: Impact of rest duration on Achilles tendon structure and function following isometric training. *Scand J Med Sci Sports*, 2018; 28(2): 436–45
- Rosengarten S, Cook J, Bryant A et al: Australian football players' Achilles tendons respond to game loads within 2 days: An ultrasound tissue characterisation (UTC) study. *Br J Sports Med*, 2015; 49(3): 183–87
- Docking S, Rosengarten S, Cook J: Achilles tendon structure improves on UTC imaging over a 5-month pre-season in elite Australian football players. *Scand J Med Sci Sports*, 2016; 26(5): 557–63
- de Jonge S, de Vos RJ, Weir A et al: One-year follow-up of platelet-rich plasma treatment in chronic achilles tendinopathy a double-blind randomized placebo-controlled trial. *Am J Sports Med*, 2011; 39(8): 1623–29
- de Jonge S, Rozenberg R, Vieyra B et al: Achilles tendons in people with type 2 diabetes show mildly compromised structure: An ultrasound tissue characterisation study. *Br J Sports Med*, 2015; 49: 995–99
- de Vos RJ, Weir A, Tol JL et al: No effects of PRP on ultrasonographic tendon structure and neovascularisation in chronic midportion Achilles tendinopathy. *Br J Sports Med*, 2011; 45: 387–92
- de Vos RJ, Heijboer M, Weinans H et al: Tendon structure's lack of relation to clinical outcome after eccentric exercises in chronic midportion Achilles tendinopathy. *J Sport Rehabil*, 2012; 21: 34–43
- Hirata K, Kanehisa H, Miyamoto-Mikami E, Miyamoto N: Evidence for inter muscle difference in slack angle in human triceps surae. *J Biomech*, 2015; 48: 1210–13
- Hug F, Lacourpaille L, Maisetti O, Nordez A: Slack of gastrocnemius medialis and Achilles tendon occurs at different angles. *J Biomech*, 2013; 46: 2534–38
- Masci L, Spang C, van Schie HTM, Alfredson H: Achilles tendinopathy – do plantaris tendon removal and Achilles tendon scraping improve tendon structure? A prospective study using ultrasound tissue characterisation. *BMJ Open Sport Exerc Med*, 2015; 1(1): e000005
- de Jonge S, Tol JL, Weir A et al: The tendon structure returns to asymptomatic values in non-operatively treated Achilles tendinopathy but is not associated with symptoms: A prospective study. *Am J Sports Med*, 2015; 43(12): 2950–58
- Robinson JM, Cook JL, Purdam C et al: The VISA-A questionnaire: A valid and reliable index of the clinical severity of Achilles tendinopathy. *Br J Sports Med*, 2001; 35: 335–41
- Docking S, Rosengarten S, Daffy J, Cook J: Structural integrity is decreased in both Achilles tendons in people with unilateral Achilles tendinopathy. *J Sci Med Sport*, 2015; 18(4): 383–87
- Wezenbeek E, Willems T, Mahieu N et al: The role of the vascular and structural response to activity in the development of achilles tendinopathy: A prospective study. *Am J Sports Med*, 2018; 46(4): 947–54
- Duenwald S, Kobayashi H, Frisch K et al: Ultrasound echo is related to stress and strain in tendon. *J Biomech*, 2011; 44: 424–29
- Wezenbeek E, Mahieu N, Willems TM et al: What does normal tendon structure look like? New insights into tissue characterization in the Achilles tendon. *Scand J Med Sci Sports*, 2017; 27: 746–53
- Handsfield G, Inouye J, Slane L et al: A 3D model of the Achilles tendon to determine the mechanisms underlying non-uniform tendon displacements. *J Biomech*, 2017; 51: 17–25
- Franz J, Slane L, Rasske K, Thelen D: Non-uniform *in vivo* deformations of the human Achilles tendon during walking. *Gait Posture*, 2015; 41: 192–97
- Slane L, Thelen D: Non-uniform displacements within the Achilles tendon observed during passive and eccentric loading. *J Biomech*, 2014; 47: 2831–35
- Chimenti R, Bucklin M, Kelly M et al: Insertional Achilles tendinopathy associated with altered transverse compressive and axial tensile strain during ankle dorsiflexion. *J Orthop Res*, 2017; 35(4): 910–15
- Thorpe C, Godinho M, Riley G et al: The interfascicular matrix enables fascicle sliding and recovery in tendon, and behaves more elastically in energy storing tendons. *J Mech Behav Biomed Mater*, 2015; 52: 85–94

Conflict of interest

None.

40. Obst S, Renault JB, Newsham-West R, Barrett R: Three-dimensional deformation and transverse rotation of the human free Achilles tendon *in vivo* during isometric plantarflexion contraction. *J Appl Physiol*, 2014; 116: 376–84
41. Bojsen-Møller J, Magnusson P: Heterogeneous loading of the human achilles tendon *in vivo*. *Exerc Sport Sci Rev*, 2015; 43(4): 190–97
42. Heyward OW, Rabello L, van der Woude L et al: The effect of load on Achilles tendon structure in novice runners. *J Sci Med Sport*, 2018; 21(7): 661–65
43. Wearing S, Smeathers J, Hooper S et al: The time course of *in vivo* recovery of transverse strain in high-stress tendons following exercise. *Br J Sports Med*, 2014; 48(5): 383–87
44. Grigg N, Wearing S, Smeathers J: Achilles tendinopathy has an aberrant strain response to eccentric exercise. *Med Sci Sports Exerc*, 2012; 44(1): 12–17
45. Parkinson J, Samiric T, Ilic MZ et al: Change in proteoglycan metabolism is a characteristic of human patellar tendinopathy. *Arthritis Rheum*, 2010; 62: 3028–35
46. Bojsen-Møller J, Hansen P, Aagaard P et al: Differential displacement of the human soleus and medial gastrocnemius aponeuroses during isometric plantar flexor contractions *in vivo*. *J Appl Physiol*, 2004; 97: 1908–14
47. Finni T, Cronin N, Mayfield D et al: Effects of muscle activation on shear between human soleus and gastrocnemius muscles. *Scand J Med Sci Sports*, 2017; 27: 26–34
48. Lohrer H, Arentz S, Nauck T et al: The Achilles tendon insertion is crescent-shaped, an *in vitro* anatomic investigation. *Clin Orthop Relat Res*, 2008; 466: 2230–37